

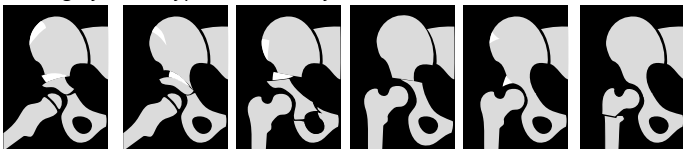## REVISION OF A TOTAL HIP ARTHROPLASTY

### history of the hip

infections: sepsis, cultures, antibiotic resistance patterns

trauma: date, mechanism, excessive axial loading

surgery: date, type of osteotomy



Salter

Pemberton

triple

Chiari

shelf

ITO

THA: date, type, manufacturer, material, implant stickers

complications: woundinfections, haematoma, fever

prolonged hospital stay, luxations, nerve damage

### general history

systemic: ASA, diabetes, AIDS, rheumatoid arthritis, radiotherapy

neurological: spasms, CVA, M.Parkinson, ALS

medication: prednison, MTX, NSAID's, coumarines, antibiotics

orthopaedic: ipsilateral total knee prosthesis

psychiatric: dementia, psychosis, alcohol/drug abuse, Münchhausen

### current complaints

pain: low back, groin, buttock, trochanter, mid thigh, knee, ankle

painfree interval, start-up pain, rest pain

function: walking distance, walking aids, climbing stairs, sitting, socks

instability: direction, luxation mechanism

### physical examination

inspection: limb length, toeing in/out, Trendelenburg, Duchenne

scars, approach, cellulitis, fistulas

ROM: flexion-extension

internal-external rotation with hip in extension and flexion

abduction-adduction

pain during ROM, pain at endpoints

palpation: local tenderness, axial loading pain, telescope mechanism

NV: sensibility, strenght: adductors, abductors, flexors, extensors

## REVISION OF A TOTAL HIP ARTHROPLASTY

### X-pelvis (AP and axial)

peri-articular: PAO's, former osteotomies, former shelfplasties

pelvic ring: intact anterior/posterior column, intact ring, limblength

cuptype: cement, material, outer diameter, inner diameter

cupposition: teardrop, abduction/adduction, anteversion/retroversion

cupdefects: wear, osteolysis, anterior column, posterior column

ball: material, diameter, conus size

stemtype: cement, offset, collar, length, straight/curved stem, taper

stemposition: subsidence, varus/valgus, ante/retroversion, pedestal

stemdefects: fausse route, cerclage, former trochanter osteotomy

### X-arthrography

radiolucent lines in Gruen zones

### technetium-99 MDP bone scan

increased uptake stem/cup after 5 minutes and 4 hours

### indium-111 IgG scan

increased uptake stem/cup after 4 hours and 24 hours

### bloodtest

leucocytes, C-reactive proteins, erythrocytes sedimentation rate

### pre-operative aspiration

date, aspiration volume, culture, antibiotic resistance, leucocytes

### fresh frozen sections

number of polymorphonuclear neutrophils per high power field

### pre-operative planning

prosthesis: revision stem, compatible taper ball, revision cup

extra-articular: meshes, screws, cerclage, plates, bonegraft

instruments: oscillating cement-remover, bone impaction set, bone mill

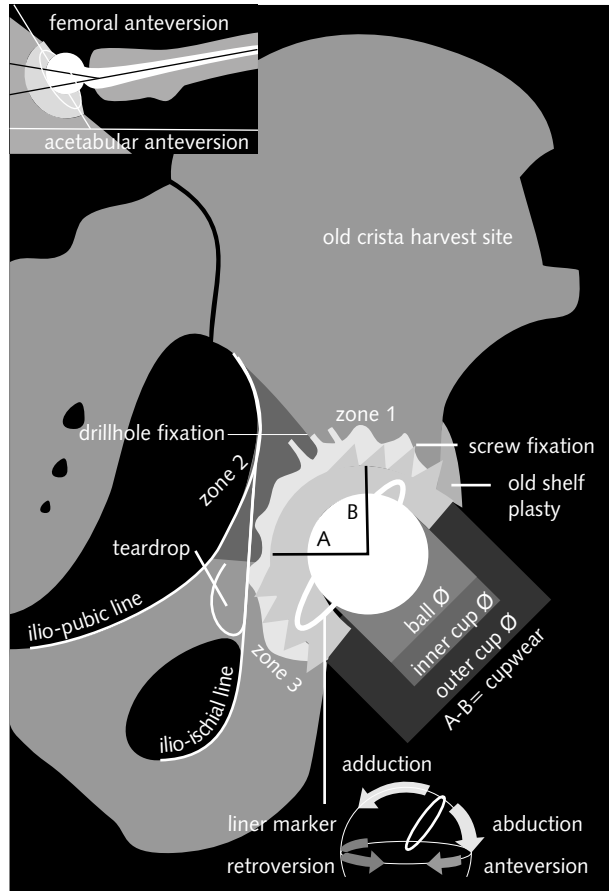
old reamer set

sponsored by: **stryker**<sup>®</sup>

## REVISION OF A TOTAL HIP ARTHROPLASTY

X-hip axial view

X-pelvis AP



## REVISION OF A TOTAL HIP ARTHROPLASTY

X-proximal femur AP

